

# Managing Elbow Dislocations

Michael Gottlieb, MD\*

\*Corresponding Author. E-mail: [michaelgottliebMD@gmail.com](mailto:michaelgottliebMD@gmail.com).



0196-0644/\$-see front matter  
Copyright © 2022 by the American College of Emergency Physicians.  
<https://doi.org/10.1016/j.annemergmed.2022.04.029>

**Continuing Medical Education** exam for this article is available at <http://www.acep.org/ACEPeCME/>.

[Ann Emerg Med. 2022;80:460-464.]

## INTRODUCTION

Elbow dislocation is one of the most common large-joint dislocations in both adults and children, with an incidence of 5.21 dislocations per 100,000 person-years.<sup>1</sup> It occurs across a wide age range but is most common between the ages of 10 and 19 years.<sup>1,2</sup> The most frequent etiology is related to sports (particularly football, wrestling, basketball, and skating), with the most common mechanism being a fall on an outstretched arm.<sup>1,3,4</sup> The majority of elbow dislocations are posterior (ie, olecranon displaced posterior to the humerus) or posterolateral, with only 1.5% being anteriorly displaced (ie, olecranon displaced anterior to the humerus).<sup>5</sup> Fractures are common, occurring in approximately half of the patients, and most commonly involve the coronoid or radial head.<sup>5</sup> Most elbow dislocations can be successfully reduced in the emergency department (ED), although patients may need operative management if there is persistent instability or the inability to reduce at the bedside.<sup>5,6</sup> Given the frequency with which elbow dislocations can present to the ED, it is important for clinicians to be aware of the approach to the management of these patients. This article is not intended to be a comprehensive review of all the aspects of the evaluation and management of patients with elbow dislocations; instead, this paper seeks to distill key facets of management based on the current literature and years of practice.

## ASSESSMENT AND IMAGING

Elbow dislocations are often suspected clinically on the basis of the mechanism and physical examination. The patient will typically present with the forearm shortened, the elbow flexed at 45 degrees, and a prominent olecranon when a posterior dislocation is present.<sup>4,7,8</sup> In contrast, the elbow will generally be shortened and held in full extension when an anterior dislocation has occurred.<sup>4</sup> Nerve injury

may be present in 16% to 22% of cases and most commonly involves the ulnar or median nerves, though the majority are transient neuropraxias that improve after reduction.<sup>9,10</sup> A median nerve injury can present with paresthesias or sensory loss over the palm (particularly to the pad of the index finger or thenar eminence) and the inability to hold the “ok” sign, whereas an ulnar nerve injury can have ring- or small-finger paresthesias or sensory loss and reduced abduction or adduction of the fingers. While rare, brachial artery rupture, transection, and thrombosis have been described with both dislocation and reduction, so it is important to assess for arterial deficits and compartment syndrome both before and after the reduction attempt.<sup>11-18</sup> Any patient with a suspected elbow dislocation should receive anteroposterior and lateral radiographs to identify the direction of the dislocation and any associated fractures. If a medial epicondyle fracture is suspected (most commonly in pediatric patients), obtain an additional oblique view to evaluate for an incarcerated fracture in the joint space.<sup>8,19,20</sup>

## ANALGESIA AND ANESTHESIA

Elbow dislocations can cause significant pain and muscle spasms. In order to facilitate the reduction, it is important to adequately control the pain and minimize the muscle spasm. Intravenous opioids are often insufficient in isolation, and the reduction is typically performed using procedural sedation.<sup>6</sup> However, intra-articular injection of local anesthetic and ultrasound-guided brachial plexus nerve blocks have also been demonstrated to successfully facilitate reduction.<sup>21,22</sup> While prior reports have used longer-acting agents (eg, bupivacaine, mepivacaine),<sup>21,22</sup> I recommend using a shorter-acting agent (eg, lidocaine) to improve the ability to examine for neurologic injury and symptoms of compartment syndrome postreduction.

## REDUCTION TECHNIQUES

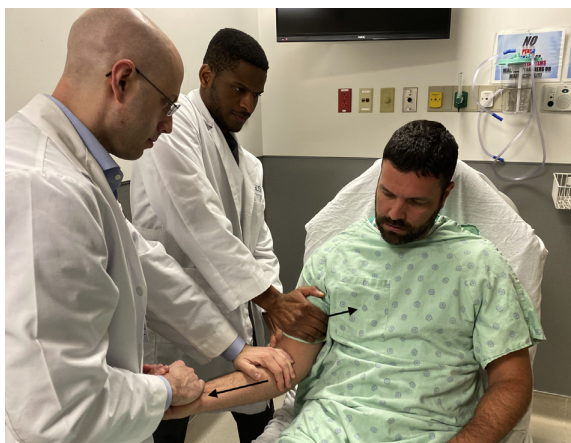In this section, I will focus on the 3 predominant techniques for posterior dislocations and 1 technique for anterior dislocations. Prior to the reduction attempt, place

the forearm in the fully supinated position and flex the elbow to 90 degrees. Shifting the arm to this position allows the distal humerus to disengage from the radial head and coronoid process, as well as to relax tension on the biceps tendon, making the reduction much easier to perform.

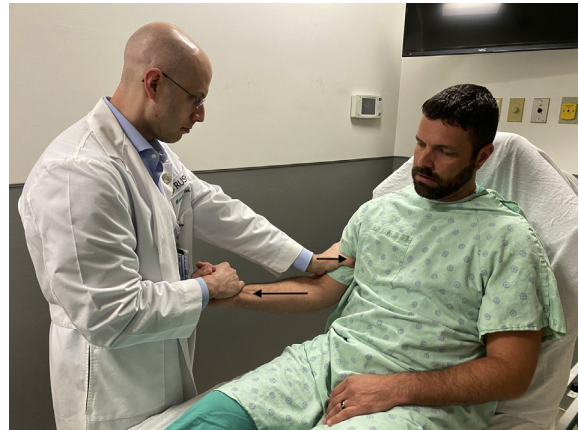### Posterior Dislocations

**Traction-countertraction technique.** One common technique is traction-countertraction. Traditionally, this involves 2 people, with 1 person applying longitudinal traction on the forearm while the second person provides countertraction on the upper arm by either pulling backward directly on the arm or using a bedsheet (Figure 1). Countertraction should be performed at the middle or distal humerus as opposed to the antecubital fossa to avoid placing excess force on the superficial nerves and vessels located in this area. This technique should be performed in a slow and controlled fashion to reduce the risk of muscle spasm. During the reduction, the clinician can also apply direct pressure on the olecranon process to guide it past the distal humerus and center it over the distal humerus (in the case of a posteromedial or posterolateral dislocation). One case series of 6 patients reported 100% reduction success with the traction-countertraction technique.<sup>23</sup>

Single-clinician versions of this technique can be performed using the clinician's contralateral arm (Figure 2) or by placing the patient's arm underneath the clinician's flexed knee to provide countertraction (Figure 3). Kumar and Ahmed<sup>24</sup> have also described a modification wherein the patient's arm is placed across their chest, using their own chest as countertraction (Figure 4). With this latter approach, the force is primarily applied to the proximal forearm and olecranon process. The authors reported a 95% reduction success rate among 21 patients with this modified technique.

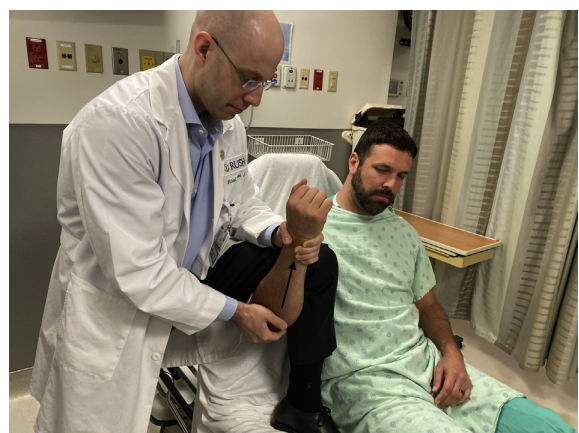

**Figure 1.** Two-person traction-countertraction technique.

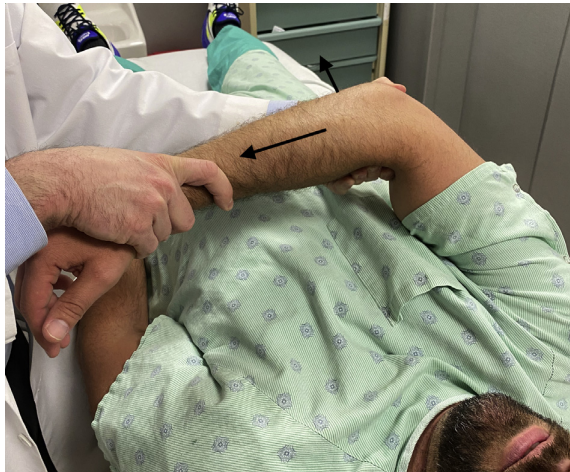

**Figure 2.** Traction-countertraction technique using the clinician's arm for countertraction.

**Leverage technique.** The leverage technique was first described by Hankin<sup>25</sup> in 1984 and offers an alternate single-person technique for the reduction of elbow dislocations. With this technique, the clinician interlocks their fingers with the patient's fingers in a clasping grip (Figure 5). If the patient has a longer forearm length than the clinician, grasp the patient's wrist instead of their fingers for this technique. The clinician then places their elbow against the distal portion of the patient's biceps muscle until tension is felt on the patient's flexed arm. Next, the clinician slowly draws the patient's arm into hyperflexion, using their elbow as a fulcrum at the patient's elbow joint. The clinician can use their other hand to guide the patient's olecranon over the distal humerus or to center the olecranon in the case of a posteromedial or posterolateral dislocation. A modification has also been described, wherein the clinician uses their contralateral hand to apply a distracting force on the patient's forearm.<sup>23</sup>



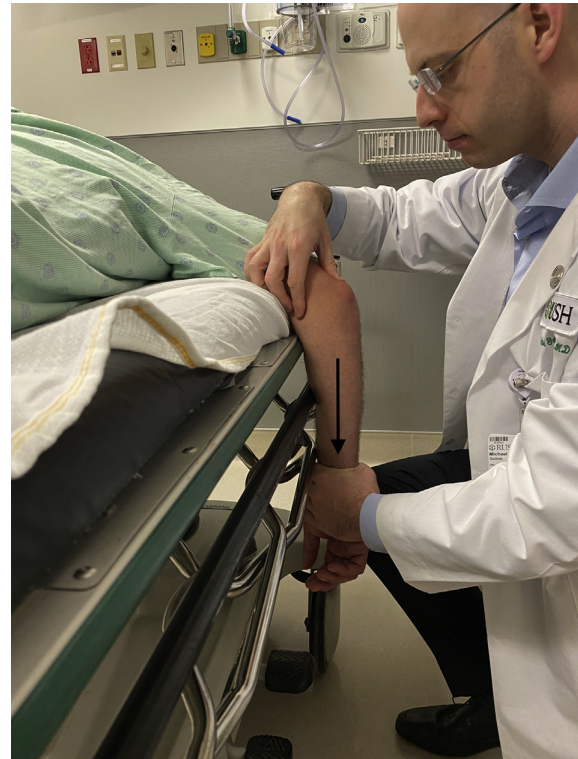**Figure 3.** Modified traction-countertraction technique using the clinician's leg for countertraction.



**Figure 4.** Modified traction-countertraction technique using the patient's body for countertraction.

The original author reported that all 77 cases were successfully reduced without complications using this technique,<sup>25</sup> and another study reported a 100% success rate among 10 dislocations.<sup>23</sup>

**Hanging-arm technique.** This technique is a modification of the Stimson technique for the shoulder and hip.<sup>26,27</sup> With this technique, the patient leans against a chair or is placed prone on a bed with their forearm hanging over the edge of the bed (Figure 6).<sup>28-30</sup> A clinician then flexes the patient's elbow to 90 degrees and applies axial traction with one hand while guiding the olecranon with the other. This will typically require 1 to 10 minutes to complete.<sup>29,30</sup> Parvin<sup>29</sup> reported the successful reduction of 20 elbows without complication using this technique. An alternate model has been described, in which

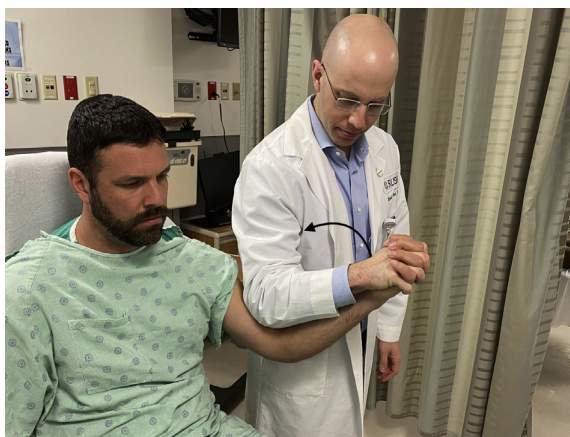


**Figure 6.** Hanging-arm technique.

pressure is directly applied to the olecranon without any traction.<sup>31</sup>

#### Anterior Dislocations

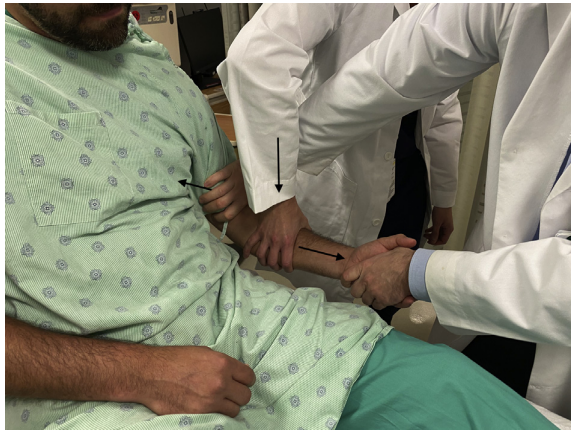The reduction of an anterior elbow dislocation can be performed using a modification to the traction-countertraction technique described above. Whereas the technique for a posterior dislocation focuses primarily on countertraction at the patient's distal humerus, the reduction of an anterior dislocation involves the primary force being applied at the patient's proximal forearm.<sup>32-34</sup> With this technique, initial in-line traction on the patient's forearm is often needed to disengage the olecranon from the anterior humerus. Once this is separated, a second person should apply posteriorly directed pressure on the patient's proximal forearm to guide the olecranon past the distal humerus (Figure 7). At this stage, the clinician may also apply anterior pressure to the distal humerus (ie, toward the olecranon) or in-line pressure on the forearm (ie, toward to humerus) to further facilitate the reduction.<sup>35</sup>



**Figure 5.** Leverage technique.

#### DISPOSITION AND AFTERCARE

After a successful reduction, repeat the neurovascular examination to assess for nerve entrapment, vascular injury,



**Figure 7.** Anterior reduction technique.

and compartment syndrome. When possible, clinicians should check for joint stability by performing varus and valgus stress testing of the joint through a full range of motion, with the forearm in a neutral position. For valgus stress testing, begin with the elbow at 20 degrees of flexion, with the humerus externally rotated. Palpate the medial joint line and then apply a valgus force at the elbow (ie, forearm directed laterally).<sup>7,8</sup> The varus stress test is performed similarly but with a medially directed force.<sup>7,8</sup> Excessive laxity compared with the contralateral extremity is considered positive. Postreduction radiographs should also be obtained to confirm adequate reduction and evaluate for associated fractures.

Elbow dislocations without evidence of instability or for which the clinician is not able to adequately assess instability can be splinted at 90 degrees with the forearm in a neutral position. Valgus instability is suggestive of medial collateral ligament (also known as the ulnar collateral ligament) injury and would benefit from immobilization with the forearm in supination, whereas varus instability is suggestive of lateral collateral ligament (also known as the radial collateral ligament) injury and would benefit from immobilization with the forearm in pronation.

Elbows with evidence of compartment syndrome or vascular occlusion require orthopedic surgery consultation. Elbows with persistent instability (ie, the elbow can be reduced but continues to redislocate) requiring immobilization beyond 45 degrees of flexion, those with suspected median nerve entrapment, and those with the inability to reduce after several attempts at closed reduction should also prompt orthopedic consultation for possible operative repair.<sup>36</sup> All other dislocations can be immobilized and discharged with orthopedic surgery follow-up within 1 week. Although elbow dislocations were

traditionally placed in casts for several weeks, more recent literature recommends early mobility, as longer immobilization has been associated with worse long-term outcomes.<sup>37,38</sup>

*The author would like to thank Dustin Brown, MD; Paul Kamsi Yonna Edemobi, MD; and Nicolas Ramsay, MD for their assistance with the photographs.*

**Supervising editor:** Steven M. Green, MD. Specific detailed information about possible conflict of interest for individual editors is available at <https://www.annemergmed.com/editors>.

**Author affiliation:** From the Department of Emergency Medicine, Rush University Medical Center, Chicago, IL.


**Funding and support:** By *Annals* policy, all authors are required to disclose any and all commercial, financial, and other relationships in any way related to the subject of this article as per ICMJE conflict of interest guidelines (see [www.icmje.org](http://www.icmje.org)). The authors report this article did not receive any outside funding or support.

## REFERENCES

1. Stoneback JW, Owens BD, Sykes J, et al. Incidence of elbow dislocations in the United States population. *J Bone Joint Surg Am.* 2012;94:240-245.
2. Neviaser JS, Wickstrom JK. Dislocation of the elbow: a retrospective study of 115 patients. *South Med J.* 1977;70:172-173.
3. Dizdarevic I, Low S, Currie DW, et al. Epidemiology of elbow dislocations in high school athletes. *Am J Sports Med.* 2016;44:202-208.
4. Pacelli LL, Guzman M, Botte MJ. Elbow instability: the orthopedic approach. *Semin Musculoskelet Radiol.* 2005;9:56-66.
5. de Haan J, Schep NW, Zengerink I, et al. Dislocation of the elbow: a retrospective multicentre study of 86 patients. *Open Orthop J.* 2010;4:76-79.
6. Sacchetti A, Senula G, Strickland J, et al. Procedural sedation in the community emergency department: initial results of the ProSCED registry. *Acad Emerg Med.* 2007;14:41-46.
7. Gottlieb M, Schiebout J. Elbow dislocations in the emergency department: a review of reduction techniques. *J Emerg Med.* 2018;54:849-854.
8. Gottlieb M, Suleiman LI. Current approach to the management of forearm and elbow dislocations in children. *Pediatr Emerg Care.* 2019;35:293-298.
9. Linscheid RL, Wheeler DK. Elbow dislocations. *JAMA.* 1965;194:1171-1176.
10. Watson-Jones R. Primary nerve lesions in injuries of the elbow and wrist. *J Bone Joint Surg Am.* 1930;12:121-140.
11. Lutter C, Pfefferkorn R, Schoeffl V. Arterial damages in acute elbow dislocations: which diagnostic tests are required? *BMJ Case Rep.* 2016;2016:bcr2016216336.
12. Ayel JE, Bonneville N, Lafosse JM, et al. Acute elbow dislocation with arterial rupture. Analysis of nine cases. *Orthop Traumatol Surg Res.* 2009;95:343-351.
13. Siebenlist S, Reeps C, Kraus T, et al. Brachial artery transection caused by closed elbow dislocation in a mature in-line skater: a case report with review of the literature. *Knee Surg Sports Traumatol Arthrosc.* 2010;18:1667-1670.
14. Thomas PJ, Noellert RC. Brachial artery disruption after closed posterior dislocation of the elbow. *Am J Orthop (Belle Mead NJ).* 1995;24:558-560.

15. Harnarayan P, Cawich SO, Harnanan D, et al. Brachial artery injury accompanying closed elbow dislocations. *Int J Surg Case Rep.* 2015;8C:100-102.
16. Slowik GM, Fitzimmons M, Rayhack JM. Closed elbow dislocation and brachial artery damage. *J Orthop Trauma.* 1993;7:558-561.
17. Long B, Koymann A, Gottlieb M. Evaluation and management of acute compartment syndrome in the emergency department. *J Emerg Med.* 2019;56:386-397.
18. Gottlieb M, Adams S, Landas T. Current approach to the evaluation and management of acute compartment syndrome in pediatric patients. *Pediatr Emerg Care.* 2019;35:432-437.
19. Harrison RB, Keats TE, Frankel CJ, et al. Radiographic clues to fractures of the unossified medial humeral condyle in young children. *Skeletal Radiol.* 1984;11:209-212.
20. Hines RF, Herndon WA, Evans JP. Operative treatment of medial epicondyle fractures in children. *Clin Orthop Relat Res.* 1987;223:170-174.
21. Heflin T, Ahern T, Herring A. Ultrasound-guided infraclavicular brachial plexus block for emergency management of a posterior elbow dislocation. *Am J Emerg Med.* 2015;33:1324.e1-4.
22. Akay S, Eksert S, Kaya M, et al. Case report: ultrasound-guided infraclavicular brachial plexus block for a case with posterior elbow dislocation. *J Emerg Med.* 2017;53:232-235.
23. Skelley NW, Chamberlain A. A novel reduction technique for elbow dislocations. *Orthopedics.* 2015;38:42-44.
24. Kumar A, Ahmed M. Closed reduction of posterior dislocation of the elbow: a simple technique. *J Orthop Trauma.* 1999;13:58-59.
25. Hankin FM. Posterior dislocation of the elbow. A simplified method of closed reduction. *Clin Orthop Relat Res.* 1984;190:254-256.
26. Gottlieb M. Managing posterior hip dislocations. *Ann Emerg Med.* 2022;79:554-559.
27. Gottlieb M. Shoulder dislocations in the emergency department: a comprehensive review of reduction techniques. *J Emerg Med.* 2020;58:647-666.
28. Lavine LS. A simple method of reducing dislocations of the elbow joint. *J Bone Joint Surg Am.* 1953;35-A:785-786.
29. Parvin RW. Closed reduction of common shoulder and elbow dislocations without anesthesia. *AMA Arch Surg.* 1957;75:972-975.
30. Meyn MA Jr, Quigley TB. Reduction of posterior dislocation of the elbow by traction on the dangling arm. *Clin Orthop Relat Res.* 1974;103:106-108.
31. Minford EJ, Beattie TF. Hanging arm method for reduction of dislocated elbow. *J Emerg Med.* 1993;11:161-162.
32. Kumar R, Sekhawat V, Sankhala SS, et al. Anterior dislocation of elbow joint-case report of a rare injury. *J Orthop Case Rep.* 2014;4:16-18.
33. Kailash S, Shanmuganathan S. Anterior dislocation of elbow with neurovascular injury: a rare case report. *J Orthop Case Rep.* 2017;7:91-94.
34. Dimantha WHD, Pathinathan K, Sivakumaran D, et al. Pediatric anterior elbow dislocation due to a rare mechanism of injury: a case report. *Int J Surg Case Rep.* 2021;85:106210.
35. Moussa MK, Alayane A, Khalaf Z, et al. Anterior elbow dislocation without associated fracture in an adolescent. *JSES Int.* 2021;5:1125-1128.
36. Mehta JA, Bain GI. Elbow dislocations in adults and children. *Clin Sports Med.* 2004;23:609-627.
37. Mehlhoff TL, Noble PC, Bennett JB, et al. Simple dislocation of the elbow in the adult. Results after closed treatment. *J Bone Joint Surg Am.* 1988;70:244-249.
38. Iordens GI, Van Lieshout EM, Schep NW, et al. Early mobilisation versus plaster immobilisation of simple elbow dislocations: results of the FuncSiE multicentre randomised clinical trial. *Br J Sports Med.* 2017;51:531-538.

### eTable of Contents Alerts



Receive the latest developments in emergency medicine via the monthly eTOC.

Request delivery of *Annals of Emergency Medicine's* e-Alerts directly to your e-mail address. This is a fast, easy, and free service to all subscribers. You will receive:

- E-mail notification of each new issue of *Annals of Emergency Medicine*, including the posting of each issue on the *Annals* Web site
- Complete Table of Contents for all new issues, hyperlinked to the Web site.